




Contents lists available at ScienceDirect

## Gynecologic Oncology

journal homepage: [www.elsevier.com/locate/ygyno](http://www.elsevier.com/locate/ygyno)

## Sentinel lymph node mapping in early-stage cervical cancer: Results from the SENTIX prospective multicenter study

Roman Kocian <sup>a,\*</sup>, Christhardt Kohler <sup>b</sup>, Jaroslav Klat <sup>c,m,1</sup>, Jiri Jarkovsky <sup>d</sup>, Ignacio Zapardiel <sup>e</sup>, Giampaolo Di Martino <sup>s,t</sup>, Luc van Lonkhuijzen <sup>f</sup>, Michal Zikan <sup>g,1</sup>, Octavio Arencibia Sanchez <sup>h</sup>, Blanca Gil-Ibanez <sup>i</sup>, Francesco Raspagliesi <sup>j</sup>, Jiri Presl <sup>k,1</sup>, Lubos Minar <sup>l,1</sup>, Radim Marek <sup>m,1</sup>, Peter Kascak <sup>n,1</sup>, Pavel Havelka <sup>o,1</sup>, Martin Michal <sup>p,1</sup>, Toon Van Gorp <sup>q,2</sup>, Kristyna Nemejcova <sup>r</sup>, Pavel Dundr <sup>r</sup>, David Cibula <sup>a,1</sup>

<sup>a</sup> Gynecologic Oncology Center, Department of Gynecology, Obstetrics and Neonatology, First Faculty of Medicine, Charles University and General University Hospital in Prague, Prague, Czech Republic

<sup>b</sup> Department of Special Operative and Oncologic Gynecology, Asklepios-Clinic Hamburg, Hamburg, Germany

<sup>c</sup> Department of Obstetrics and Gynecology, University Hospital Ostrava, Ostrava, Poruba, Czech Republic

<sup>d</sup> Institute of Biostatistics and Analyses, Faculty of Medicine, Masaryk University, Brno, Czech Republic

<sup>e</sup> Gynecologic Oncology Unit, La Paz University Hospital, Madrid, Spain

<sup>f</sup> Department of Gynecological Oncology, Amsterdam University Medical Center, Center for Gynecological Oncology Amsterdam, Amsterdam, Netherlands

<sup>g</sup> Department of Obstetrics and Gynecology, Bulovka University Hospital, First Faculty of Medicine, Charles University, Prague, Czech Republic

<sup>h</sup> Department of Gynecologic Oncology, University Hospital of the Canary Islands, Las Palmas de Gran Canaria, Spain

<sup>i</sup> Unit of Gynecological Oncology, Institute Clinic of Gynecology, Obstetrics and Neonatology (ICGON), Hospital Clinic of Barcelona, Barcelona, Spain

<sup>j</sup> Department of Gynecological Oncology, Fondazione IRCCS Istituto Nazionale dei Tumori di Milano, Italy

<sup>k</sup> Department of Gynecology and Obstetrics, University Hospital Pilsen, Charles University, Faculty of Medicine in Pilsen, Pilsen, Czech Republic

<sup>l</sup> Department of Gynecology and Obstetrics, Faculty of Medicine, Masaryk University, Brno, Czech Republic

<sup>m</sup> Department of Obstetrics and Gynecology, Faculty of Medicine and Dentistry, Palacky University, University Hospital Olomouc, Olomouc, Czech Republic

<sup>n</sup> Department of Gynecology and Obstetrics, Slovak Medical University and University Hospital, Bratislava, Slovak Republic

<sup>o</sup> Department of Obstetrics and Gynecology, KNTB a.s, Zlin, Czech Republic

<sup>p</sup> Department of Obstetrics and Gynecology, Hospital Ceske Budejovice, JSC, Ceske Budejovice, Czech Republic

<sup>q</sup> Department of Gynaecological Oncology, University Hospital Leuven, Leuven Cancer Institute, Leuven, Belgium

<sup>r</sup> Department of Pathology, First Faculty of Medicine, Charles University and General University Hospital in Prague, Prague, Czech Republic

<sup>s</sup> Gynecologic Oncology Surgical Division, Humanitas San Pio X, Milan, 20159, Italy

<sup>t</sup> Gynecologic Unit, IRCCS Fondazione San Gerardo dei Tintori, 20900 Monza, Italy

### HIGHLIGHTS

- Bilateral SLN detection rate reached 92.3 %, unaffected by BMI, tumor histology, or prior conization.
- Most SLNs (91.6 %) were located at pelvic level I, below the interiliac bifurcation.
- SLNs at the pelvic level II were rare (2.7 %), and isolated positive ones even rarer (1.3 %).
- Bilateral detection in tumors 2–4 cm remained high (92 %) despite being significantly lower than in smaller tumors (97 %).
- SLN biopsy demonstrated reproducibility and anatomical predictability in tumors ≤4 cm.

### ARTICLE INFO

#### Article history:

Received 25 August 2025

Received in revised form 27 September 2025

Accepted 30 September 2025

Available online xxxx

#### Keywords:

Cervical cancer

Sentinel lymph node biopsy

\* Corresponding author.

E-mail address: [Roman.Kocian@vfn.cz](mailto:Roman.Kocian@vfn.cz) (R. Kocian).

<sup>1</sup> Central and Eastern European Gynecologic Oncology Group (CEGOG).

<sup>2</sup> Belgium and Luxembourg Gynecological Oncology Group (BGOG).

### ABSTRACT

**Objective.** To assess sentinel lymph node (SLN) bilateral detection rate, anatomical distribution, and tracer performance in early-stage cervical cancer patients undergoing primary surgery, based on data from the prospective multicenter SENTIX trial.

**Methods.** Patients with FIGO 2018 stage IA1 (LVSI+) to IB2 cervical cancer and no suspicious lymph nodes on preoperative imaging were enrolled in the SENTIX trial. SLN biopsy was performed using blue dye (BD), radiocolloid (RC), indocyanine green (ICG), or their combinations. Only patients with successful bilateral SLN detection and negative intraoperative frozen section proceeded to radical hysterectomy or fertility-sparing surgery. SLN locations and metastatic status were documented by anatomical region and centrally reviewed for consistency.

SLN mapping  
Early-stage  
Bilateral detection  
SENTIX trial

**Results.** Among 724 patients who underwent SLN biopsy, the overall bilateral detection rate was 92.3 %, with the highest rate (100 %) achieved using ICG and RC combination. If mapping-failure cases were considered, the bilateral detection rate would be 84.6 %. Most SLNs (91.6 %) were located at pelvic level I, predominantly in the external iliac and interiliac regions. SLNs above the interiliac bifurcation were infrequent (2.7 %), and isolated positive SLNs in pelvic level II were rare (1.3 %). No SLNs were identified in paraaortic regions. Bilateral detection was unaffected by BMI, histology, or prior conization. Although detection was slightly lower in tumors >2 cm, bilateral rates exceeded 90 %.

**Conclusions.** SLN mapping demonstrated high bilateral detection across tracers and patient subgroups. Nearly all SLNs were confined to pelvic level I, underscoring anatomical predictability. These results demonstrate reproducible SLN mapping in tumors ≤4 cm and may help inform individualized surgical planning.

© 2025 Elsevier Inc. All rights are reserved, including those for text and data mining, AI training, and similar technologies.

## 1. Introduction

Sentinel lymph node (SLN) biopsy has become an integral part of nodal staging in gynecologic oncology. In endometrial and vulvar cancers, it is already established as the standard of care, offering reduced morbidity without compromising oncologic outcomes. In contrast, early-stage cervical cancer has traditionally relied on systematic pelvic lymphadenectomy (PLND) as the standard surgical approach, despite growing evidence that SLN biopsy may offer a less radical but equally safe alternative [1].

Until recently, the limited availability of large-scale prospective data has hindered the broader adoption of SLN biopsy in cervical cancer. This gap has now been addressed by three independent multicenter prospective trials - SENTIX (CEEGOG-CX01; ENGOT-CX2), SENTICOL III, and PHENIX – each evaluating the oncologic safety of SLN biopsy without additional PLND in early-stage cervical cancer [2–4]. While differing in methodology, these studies are interpreted in the context of landmark trials such as LACC and SHAPE, which have redefined surgical radicality in cervical cancer treatment [5,6].

Among these, SENTIX was the first to complete patient accrual and report outcomes. It prospectively evaluated SLN biopsy alone, omitting systematic PLND, in patients with early-stage cervical cancer without preoperative signs of lymph node metastasis. Final results confirmed a 2-year recurrence rate of 6.1 % and overall survival exceeding 97 %, outcomes comparable to those observed in historical cohorts of patients treated with systematic pelvic lymphadenectomy. These findings have been internationally endorsed and have contributed to the paradigm shift in nodal staging strategies [7].

The safety of this approach relies on the accuracy and reproducibility of SLN mapping. A pre-planned interim analysis of the first 395 patients,

published in 2020, demonstrated high bilateral detection rate (DR) and consistent anatomical distribution of SLNs [8]. The final analysis, now based on a nearly double the cohort size, offers a unique opportunity to assess mapping performance by tracer, anatomical location, and patient or tumor-related factors. Additionally, we examined whether factors such as patient BMI, tumor size, histological subtype, and prior conization influence SLN detection rate.

## 2. Materials and methods

### 2.1. Study design and setting

The SENTIX trial (CEEGOG-CX-01; ENGOT-CX2; NCT02494063) is a prospective, international, multicenter observational study coordinated by the Central and Eastern European Gynecologic Oncology Group (CEEGOG) within the ENGOT framework. The primary aim was to assess the oncologic safety of SLN biopsy alone, omitting systematic pelvic lymphadenectomy (PLND), in patients with early-stage cervical cancer. The study protocol was published at the trial initiation as a “trial-in-progress” paper to outline its methodology and objectives [2]. Between June 2016 and October 2020, 47 centers across 18 countries enrolled eligible patients. All centers met predefined requirements for surgical volume and prior SLN mapping experience. Final oncological outcomes were published in 2025 [7].

This paper focuses on SLN biopsy, evaluating bilateral DR, anatomical distribution, and tracer performance. It includes all patients in whom SLN biopsy was successfully performed, and complete mapping data were available. The study design, including eligibility and cohort structure, is summarized in Fig. 1.

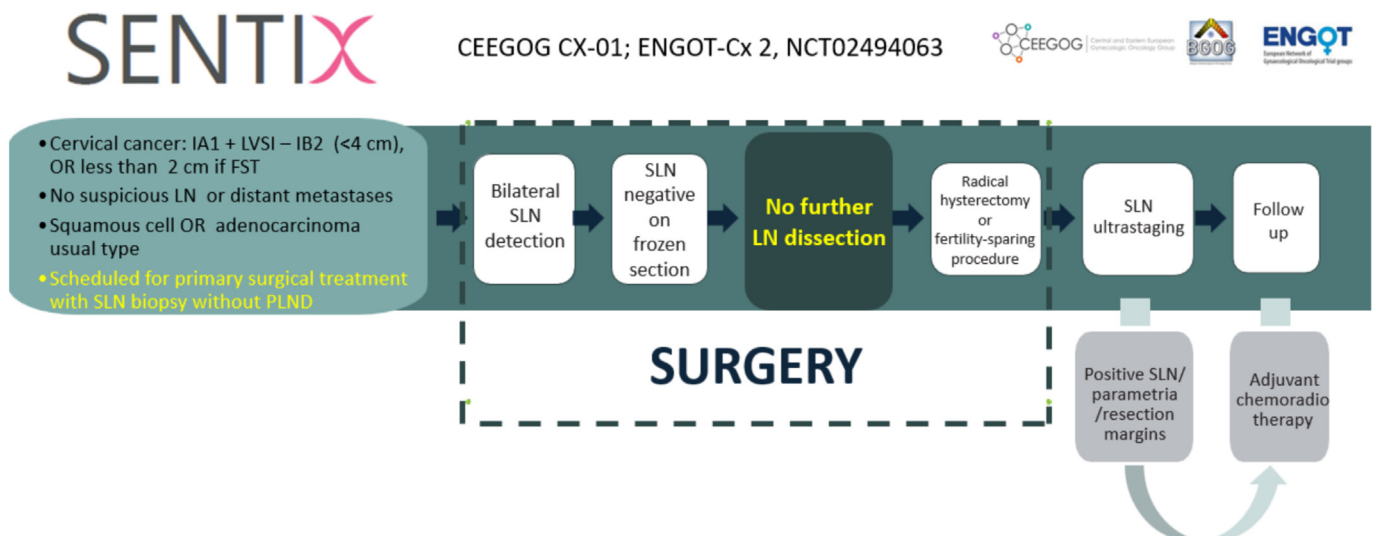


Fig. 1. Sentix study design.

## 2.2. Study population

Eligible patients had histologically confirmed cervical cancer (FIGO 2018 stages IA1 with lymphovascular space invasion to IB2, with tumor diameter < 4 cm, or  $\leq 2$  cm for fertility-sparing procedures). Accepted histologic types included squamous cell carcinoma, HPV-associated adenocarcinoma, and adenosquamous carcinoma; adenosquamous carcinoma was initially allowed but excluded by the second protocol amendment in 2018. Preoperative evaluation by expert ultrasound and/or MRI was mandatory to rule out suspicious pelvic or paraaortic lymph nodes.

Patients were excluded if they had prior pelvic radiotherapy, neoadjuvant chemotherapy, rare histologic variants (e.g., mesonephric, neuroendocrine), or HIV infection. Only patients with successful bilateral SLN detection were included in this mapping-focused analysis.

To ensure procedural consistency and high mapping quality, centers were required to have performed SLN biopsy in at least 15 prior cervical cancer cases and to treat a minimum of 10 patients with invasive cervical cancer per year. The flow of patients through screening, enrollment, and analysis is shown in the CONSORT diagram (Fig. 2).

## 2.3. SLN mapping and tracers

Any of the three commonly used tracers was eligible for use in SLN detection—blue dye (BD), radiocolloid (RC), or indocyanine green (ICG), either alone or in combination, based on institutional standards and surgeon preference. Tracer type and concentration were not centrally fixed and were left to institutional preference. All centers used validated commercial preparations and adhered to a standardized injection site. Most centers followed pre-existing institutional protocols for SLN mapping. Preoperative lymphoscintigraphy was not required. The protocol mandated SLN identification before any further retroperitoneal dissection. The anatomical location of each SLN was recorded intraoperatively according to standardized pelvic regions: external iliac, interiliac (corresponding to the proximal obturator chain), common iliac, and presacral. SLNs were also classified by level: level I (below the interiliac bifurcation) and level II (cranial to it). Any atypical SLN localization, including possible paraaortic drainage, could be noted in the optional free-text comment field of the surgical report (SENTIX postoperative Form 3).

## 2.4. SLN mapping technique and data collection

SLN biopsy was performed according to a standardized surgical protocol defined in the SENTIX study. Cervical injection of the tracer (BD,

RC, or ICG) was performed slowly into the stroma at four quadrants (or at 3 and 9 o'clock), both superficially and submucosally. Intraoperatively, SLNs were identified either visually or using a gamma probe or near-infrared fluorescence imaging. All identified SLNs were removed prior to any further dissection. Care was taken to avoid disruption of lymphatic channels during SLN identification. The retroperitoneum was opened above the external iliac vessels, and both the paravesical and pararectal spaces were explored to localize potential SLNs.

SLNs were classified intraoperatively by anatomical location (external iliac, interiliac, common iliac, presacral) and pelvic level (I or II, defined by the interiliac bifurcation). Surgical and pathological mapping data, including laterality, anatomical labeling, number of SLNs, tracer used, operative time, and complications, were entered by the surgeon into standardized postoperative forms (FORM 3) within the SENTIX Information System (SIS) and monitored in real time to ensure completeness and internal consistency (Supplementary Fig. 2).

## 2.5. Classification of SLN metastases

Metastatic deposits within SLNs were categorized according to TNM classification. Macrometastasis (MAC) was defined as metastasis >2 mm in diameter, micrometastasis (MIC) was metastasis >0.2 and  $\leq 2$  mm, and isolated tumor cells (ITCs) were defined as individual tumor cells or small clusters of cells up to 0.2 mm in diameter or < 200 cells.

## 2.6. Outcomes

The primary objective of this analysis was to assess the bilateral SLN detection rate across the full cohort. Additional endpoints included the anatomical distribution of all SLNs and metastatic SLNs by pelvic level, as well as detection performance across different tracer types and combinations. Secondary objectives were to evaluate whether clinical variables, including tumor size ( $\leq 2$  cm vs >2 cm), histologic subtype, body mass index (BMI), and prior diagnostic conization, affected the bilateral SLN detection.

## 2.7. Statistical analysis

Descriptive statistics were used to summarize baseline characteristics and SLN detection outcomes. Categorical data were presented as frequencies and percentages; while continuous variables were reported as means with standard deviations or medians with interquartile ranges, as appropriate. Bilateral detection rates across subgroups were compared using Pearson's chi-square test. All statistical analyses were performed using SPSS software version 25.0 (IBM Corp., Armonk, NY). A two-sided *p*-value of <0.05 was considered statistically significant.

## 3. Results

### 3.1. Study population and surgical characteristics

A total of 816 patients were enrolled in the SENTIX trial. After the exclusion of 102 patients who did not meet the predefined eligibility criteria or lacked SLN mapping data, 714 patients were included in this analysis. Most patients (72 %) were treated at high-capacity centers enrolling  $\geq 20$  patients. Minimally invasive (laparoscopic or robotic) and open surgery were both permitted at trial initiation in 2016. After publication of the LACC trial in 2018, a protocol amendment recommended open surgery; nevertheless, 63 % of procedures remained minimally invasive.

Radical hysterectomy was performed in 568 patients, of which 50 % were conducted using a nerve-sparing technique (type C1). Fertility-sparing procedures were performed in 66 patients, including vaginal radical trachelectomy (50 %), simple trachelectomy (29 %), conization (16 %), and abdominal radical trachelectomy (4 %). Most tumors

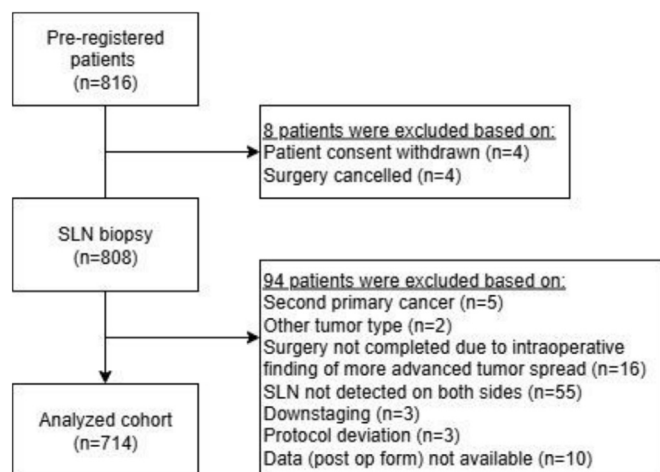


Fig. 2. Patient flow.

were squamous cell carcinoma (69.3 %), followed by usual-type HPV-related adenocarcinoma (28.6 %). Tumors  $\leq 2$  cm were present in 63.6 % of patients, and diagnostic conization had been performed in 54.4 %. Obesity (BMI  $>30$ ) was present in 19 % of the cohort. Baseline clinical and demographic characteristics of all patients who underwent surgical treatment ( $n = 732$ ) are summarized in Table 1.

### 3.2. SLN detection rate

Bilateral SLN detection was achieved in 669 of 724 patients, yielding a DR of 92.3 %. The median number of SLNs identified per patient was 3, with no significant difference between left and right pelvic sides. This high DR was consistent across all participating centers. Detection efficacy remained consistently high across subgroups stratified by BMI, histologic subtype, or prior diagnostic conization. A statistically significant difference in bilateral detection was observed for postoperative tumor size: 97.1 % in tumors  $\leq 2$  cm versus 92.0 % in tumors  $>2$  cm ( $p = 0.005$ ). Although a statistically significant difference in bilateral detection was observed by tumor stage ( $p = 0.045$ ), the highest rate was in patients with IA1 with LVSI (100 %), followed by IA2 (94.2 %) and IB1 (91.7 %). Detection rates remained high across all stages ( $\geq 90$  %). Factors potentially influencing bilateral detection are analyzed in Table 3. No difference was observed in SLN bilateral detection rate for individual

centers with high numbers and centers with less than 10 patients included (Supplementary Fig. 1). This likely reflects the inclusion of experienced centers with extensive SLN mapping practice outside the study setting. As per protocol, only patients with bilateral SLN detection were eligible for further surgery and primary analysis. However, we examined the subgroup of 55 excluded patients to assess potential bias. Among them, 44 had unilateral mapping, and 11 had no SLN detected. If all 779 enrolled patients (including mapping failures) were considered, the overall bilateral detection rate would be 84.6 % (659/779), compared to 92.3 % (659/714) in the analyzed cohort. Associations between bilateral detection and clinical variables (tumor size, histology, BMI, prior conization) remained consistent when including these cases. No new predictive factors for mapping failure were identified.

### 3.3. Tracer-specific mapping performance

Tracer-specific bilateral detection performance is summarized in Table 2. The highest bilateral DR (100 %) was achieved using a combination of RC and ICG. Other dual-tracer combinations also performed well, including BD + ICG (97.5 %), BD + RC (90.1 %), and BD + RC + ICG (95.7 %). ICG alone achieved 92.2 %, RC alone 88.9 %, while blue dye alone had the lowest detection rate (84.6 %). The full breakdown of bilateral detection rates for each tracer strategy is available in Supplementary Table 1.

### 3.4. Anatomical distribution of SLNs

The majority of SLNs (91.6 %) were located in pelvic level I, primarily in the external iliac and interiliac regions. Only 2.7 % of SLNs were identified exclusively in pelvic level II, i.e., above the interiliac bifurcation and without any SLN in level I. No SLNs were documented in paraaortic areas. The anatomical distribution of all SLNs and positive SLNs is illustrated in Fig. 3.

**Table 1**

Patient characteristics ( $n = 732$ ).

Characteristics	n (%) / mean <sup>a</sup> / median <sup>b</sup> (5–95th percentile) <sup>c</sup>
<b>No. of patients enrolled per site</b>	
$\leq 10$	125 (17.1 %)
11–20	81 (11.1 %)
$> 20$	526 (71.9 %)
<b>Age</b>	45 <sup>a</sup> / 43 <sup>b</sup> (29; 68) <sup>c</sup>
<b>BMI categories</b>	
$\leq 25$	423 (57.8 %)
25–30	168 (23.0 %)
$> 30$	141 (19.3 %)
<b>ECOG</b>	
0	704 (96.2 %)
1	28 (3.8 %)
<b>Diagnostic method</b>	
Biopsy	327 (45.0 %)
Conization	405 (55.0 %)
<b>Tumor stage (FIGO 2009)</b>	
IA1 + LVSI	39 (5.3 %)
IA2	71 (9.7 %)
IB1	621 (84.8 %)
Not available	1 (0.1 %)
<b>Grading</b>	
G1	180 (24.6 %)
G2	374 (51.1 %)
G3	159 (21.7 %)
Not available	19 (2.6 %)
<b>Histology</b>	
Squamous cell carcinoma	510 (69.7 %)
Adenocarcinoma usual type (HPV related)	212 (29.0 %)
Adenosquamous carcinoma	9 (1.2 %)
Not available	1 (0.1 %)
<b>Maximum tumor diameter on final histology [mm]</b>	
	17.4 <sup>a</sup> / 15.0 <sup>b</sup> (2.4; 40.0) <sup>c</sup>
<b>Tumor size postoperative</b>	
$\leq 2$ cm	418 (57.1 %)
2–4 cm	235 (32.1 %)
$> 4$ cm	26 (3.6 %)
Not available	53 (7.2 %)
<b>Surgical approach</b>	
Minimally invasive (laparoscopic or robotic)	462 (63.0 %)
Open (laparotomy)	270 (37.0 %)
<b>LVSI</b>	
No	473 (64.6 %)
Yes	216 (29.5 %)
Not available	43 (5.9 %)

**Table 2**

SLN detection ( $N = 714$ ; patients with surgery and postoperative form).

Characteristics	n (%) / median (5–95th percentile)
<b>Bilateral SLN detection</b>	
No	55 (7.7 %)
Yes	659 (92.3 %)
<b>Detection method</b>	
BD	76 (10.6 %)
RC	28 (3.9 %)
ICG	200 (28.0 %)
BD + RC	222 (31.1 %)
BD + ICG	79 (11.1 %)
RC + ICG	65 (9.1 %)
BD + RC + ICG	44 (6.2 %)
<b>No of SLN</b>	
	4.1 / 3.0 (2.0; 10.0)
<b>Number of SLN</b>	
0	15 (2.1 %)
1	10 (1.4 %)
2	224 (31.4 %)
3	152 (21.3 %)
4	104 (14.6 %)
$> 4$	183 (25.3 %)
Missing	26 (3.6 %)
<b>No. of patients with positive SLN</b>	
Unilateral	83 (11.6 %)
Bilateral	19 (2.7 %)
Side not available	9 (1.3 %)
Total	111 (15.5 %)
<b>No. of positive SLN</b>	
0	612 (85.7 %)
1	77 (10.8 %)
2	19 (2.7 %)
3	6 (0.8 %)
Positive, no. not available	9 (1.3 %)

**Table 3**  
Factors influencing bilateral SLN detection.

	Bilateral SLN detection		p
	no (N = 55)	yes (N = 659)	
<b>BMI categories</b>			
≤25	29 (7.0 %)	386 (93.0 %)	0,654
25–30	15 (9.3 %)	147 (90.7 %)	
30+	11 (8.0 %)	126 (92.0 %)	
<b>Tumor stage (FIGO 2009)</b>			
IA1 + LVSI	0 (0.0 %)	34 (100.0 %)	<b>0,045</b>
IA2	4 (5.8 %)	65 (94.2 %)	
IB1	51 (8.3 %)	560 (91.7 %)	
<b>Tumor size postoperative</b>			
≤2 cm	12 (2.9 %)	402 (97.1 %)	<b>0,005</b>
>2 cm	18 (8.0 %)	207 (92.0 %)	
<b>Diagnostic conization</b>			
Yes	31 (7.6 %)	379 (92.4 %)	0.957
No	24 (7.2 %)	310 (92.8 %)	

3.5. SLN metastases

Metastatic involvement of SLNs was identified in 81 of 647 patients (12.5 %), comprising 43 cases (6.6 %) of macrometastases (MAC), 38 (5.9 %) of micrometastases (MIC), and 22 (3.4 %) of isolated tumor cells (ITC). The vast majority of positive SLNs were located in pelvic level I. Among the 81 patients with MAC or MIC (pN1), 46 (56.8 %) were detected intraoperatively (36 MAC and 10 MIC). The remaining 35 cases (7 MAC, 28 MIC) were diagnosed through postoperative ultrastaging. An additional 22 patients were found to have ITCs only. The probability of an isolated positive SLN located exclusively in level II (i.e., between the interiliac and aortic bifurcation) was extremely low, occurring in only 1.3 % of all mapped patients. This analysis uses the subgroup of 647 patients with complete SLN ultrastaging, as described in our previous publication on pathological assessment of sentinel nodes [9].

4. Discussion

Our findings confirm high and consistent bilateral detection, anatomically predictable SLN distribution, and robust performance across tracer types and patient subgroups, that are prerequisites for the safe implementation of SLN biopsy as a standard nodal staging procedure in early-stage cervical cancer.

An interim analysis on the first 395 patients previously described SLN detection performance [8]. Intraoperative SLN pathological examination, frozen section sensitivity, and SLN ultrastaging were reported separately [9,10]. The current report, based on the total cohort of 714 patients, offers enhanced statistical power and broader subgroup validation, including evaluation of tracer efficacy and predictors of bilateral detection.

A bilateral detection rate of 92.3 % is among the highest reported in a prospective multicenter setting in cervical cancer. This high rate remained stable over the study period, with no increase in detection rate associated with later patient’s registration into the study, suggesting the absence of a learning curve for centers where ≥15 SLN biopsies have been performed (Supplementary Fig. 1). These results likely reflect the rigorous selection of participating sites with established SLN experience, high case volumes, and routine use of mapping in gynecologic oncology practice.

SLN mapping in SENTIX study adhered to the core principle of targeted nodal sampling. A median of three SLNs were identified per patient, typically within a defined anatomical zone. SLNs were predominantly located in pelvic level I, with 654 of 714 patients (91.6 %) having SLNs in the external or interiliac regions. Isolated level II drainage (above the interiliac bifurcation and below the aortic bifurcation) was identified in only 19 patients (2.7 %). Isolated metastatic SLNs in level II (i.e., without involvement of level I) were identified in just 9 of 714 patients (1.3 %). No SLNs were documented in paraaortic locations. However, as paraaortic lymph nodes were not systematically removed or evaluated, we cannot exclude the

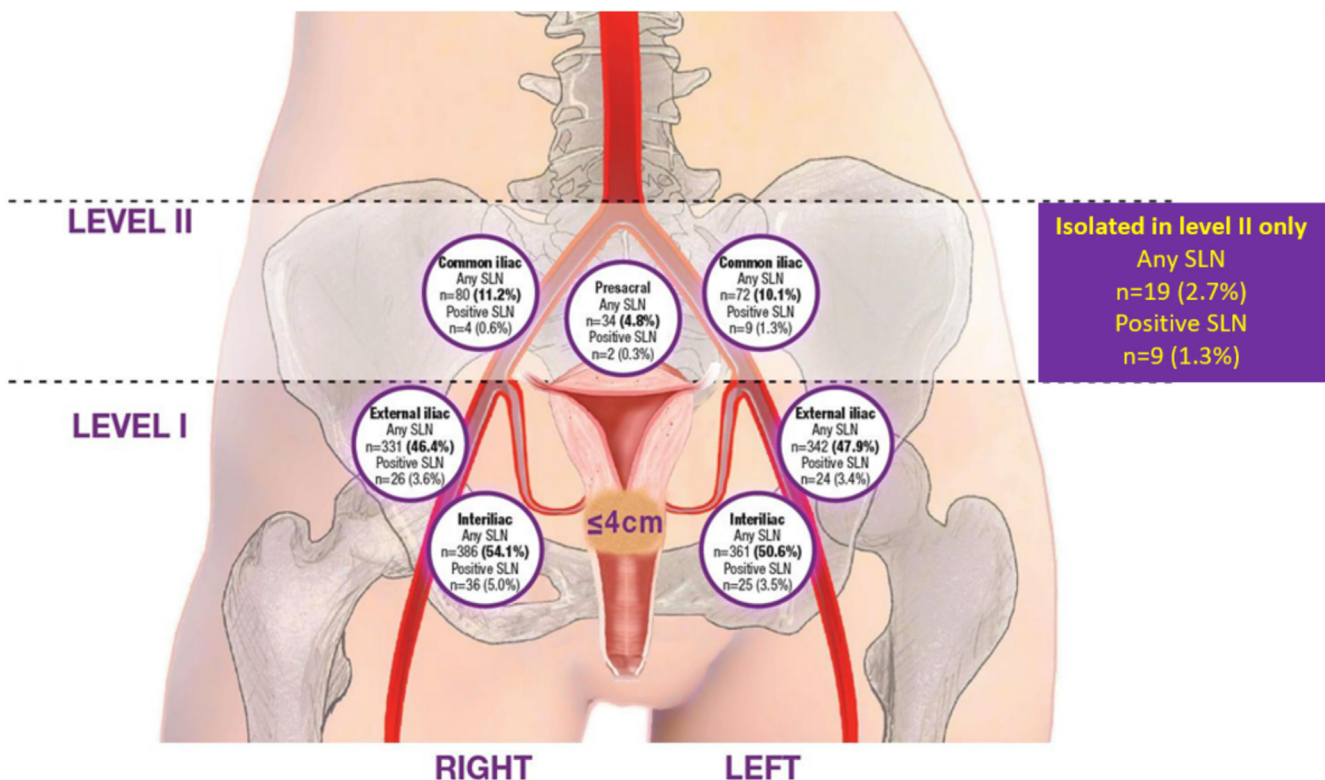


Fig. 3. Anatomical distribution of SLNs and positive SLNs.

possibility of metastases in this region. These results reinforce the anatomical predictability of lymphatic drainage in early-stage cervical cancer and support limiting nodal dissection to pelvic level I when bilateral mapping is not achieved.

High bilateral DR were maintained across all clinical subgroups, including those with obesity, non-squamous histology, and prior diagnostic conization. Notably, prior diagnostic conization, performed in over half of the SENTIX cohort, had no negative effect on bilateral SLN detection. Although not directly compared in this study, these findings suggest that excisional procedures may not compromise SLN mapping and could be preferred over core biopsy in small tumors.

DR was lower in tumors >2 cm. This is in line with several previous studies. Balaya et al. identified tumor size  $\geq 20$  mm as an independent predictor of bilateral mapping failure in the SENTICOL I & II cohorts (OR 0.46;  $p = 0.048$ ) [11]. Similar associations were reported by Bizzarri et al., where tumor size >20 mm significantly reduced bilateral SLN detection (OR 0.52;  $p = 0.023$ ), and by Zhang et al., who found tumor size >2 cm to be a predictive factor for unsuccessful mapping [12,13]. In contrast, Dostálek et al. reported comparable bilateral DRs across tumor size categories (<2 cm: 79 %, 2–3.9 cm: 83 %,  $\geq 4$  cm: 76 %;  $p = 0.460$ ), concluding that reliable mapping can be achieved in larger tumors when tracer injection is appropriately adapted [14]. These findings confirm that while larger tumor size may reduce mapping efficiency, high bilateral detection remains feasible, as reflected by our >90 % DR in patients with tumors >2 cm.

Tracer-specific analysis demonstrated excellent performance across all routinely used agents. Dual-agent combinations, particularly RC + ICG (100 %) and BD + ICG (97.5 %), achieved the highest detection rates. ICG alone yielded 92.2 %, while blue dye and radiocolloid as single agents achieved 84.6 % and 88.9 %, respectively. These findings underscore the benefit of using dual-tracer protocols, though all tracers proved effective in experienced hands. Despite minor variability in tracer concentrations and injection techniques, consistently high bilateral detection was achieved, supporting the robustness of SLN mapping across real-world settings. Importantly, BD alone was only slightly inferior to ICG, supporting a flexible approach to tracer selection based on local availability and surgical expertise.

A bilateral detection rate of 92.3 % was consistently achieved in SENTIX, confirming feasibility of SLN mapping across all routinely used tracers. This detection rate is among the highest reported in prospective multicenter studies and aligns with, or exceeds, the best results published to date. In a multicenter Italian cohort of 144 patients, Buda et al. (2016) reported a significantly higher bilateral DR with ICG (98.5 %) compared to radiocolloid (81.0 %) and blue dye (78.1 %) [15]. Di Martino et al. reported a similarly favorable bilateral DR with ICG (91.7 %) [16]. Other high-performing ICG-based studies include Imboden (95.5 %), Persson (94.5 %), and Aoki (88.3 %), predominantly performing laparoscopic or robotic procedures [17–19].

Conversely, some studies using ICG have shown lower bilateral DRs, such as Beavis (86.7 %), Kim (85.4 %), and Papatthemelis (83.3 %) [20–22]. Bizzarri et al. observed a markedly lower DR of 74.1 % in a cohort with one-third of patients undergoing open surgery, and Fernandez et al. reported an 89 % rate in an open cohort [23,24]. A comprehensive 2024 review by Laufer et al. concluded that ICG consistently outperforms radiocolloid and blue dye when combined with near-infrared imaging, particularly in minimally invasive settings. The most consistent results were observed in studies using an ICG concentration of 1.25 mg/mL and a total injection volume of 4 mL [25]. While dual-tracer protocols remain optimal, current evidence confirms that ICG alone provides robust, reproducible results, supporting its role as the primary tracer in modern SLN mapping protocols.

Recent prospective studies evaluating SLN biopsy in early-stage cervical cancer reported lower detection rates than the SENTIX study or did not mandate SLN biopsy. The PHENIX-I trial, a randomized study from China, confirmed oncologic safety of SLN biopsy alone, with a 3-year DFS of 96.8 %. However, the bilateral DR in PHENIX reached only

82.6 %, which may correspond to the predominant use of methylene blue (85 % of cases) [4,26]. The SENTICOL-2 trial, a multicenter randomized study conducted in France and Belgium, reported a bilateral detection rate of 86.5 % using primarily a combination of radiocolloid and blue dye. While the trial demonstrated significantly reduced morbidity in the SLN-only group, pathologic assessment was not centrally reviewed, and SLN ultrastaging was not uniformly standardized across participating centers [27]. While the LACC and SHAPE trials have redefined surgical radicality, neither trial addressed SLN mapping. SLN biopsy was optional in SHAPE (performed in only 38 %) and not addressed in LACC [6]. Notably, the LACC trial did not report the proportion of patients who underwent SLN biopsy, preventing any assessment of its role or potential impact on outcomes [5].

## 5. Strengths and limitations

A major strength of this study is its pragmatic, real-world design. Participating centers used their routine SLN mapping techniques and preferred tracers. Substantial effort was made to ensure procedural standardization: an instructional video was provided to all sites, detailing tracer injection and SLN detection technique. The prospective multicenter design and inclusion of the largest SLN mapping cohort to date enhance the generalizability of findings. Limitations include observational design, which is, however, mostly relevant for the assessment of surgical outcomes. Tracer selection was not randomized, but the robust bilateral detection across all strategies supports their reliability in clinical practice. While only patients with bilateral detection were eligible for primary analysis as per protocol, mapping-failure cases (i.e., unilateral or no SLN detection) were separately analyzed and did not affect associations between detection and clinical variables such as tumor size, prior conization, or BMI. One limitation concerns documentation of atypical SLN locations. While the protocol recommended careful intraoperative inspection of afferent lymphatic pathways, paraaortic SLNs could not be specifically reported in the postoperative form (Supplementary Fig. 2). Although a free-text field was available, no such drainage was recorded in any case, and its underreporting cannot be excluded.

## 6. Conclusion

This study confirms that SLN mapping in early-stage cervical cancer is highly reproducible, anatomically predictable, and consistently achieves high bilateral detection rates across patient subgroups, unaffected by histological subtype, body mass index, or prior conization. Bilateral SLN detection was achieved in over 92 % of patients, with 91.6 % of nodes located below the interiliac bifurcation (pelvic level I). Although bilateral detection was significantly lower in tumors >2 cm, detection rates remained above 90 %, supporting the feasibility of SLN mapping even in larger tumors. Mapping performance was consistently high across all commonly used tracers, with no single agent demonstrating clear superiority. These results support the use of SLN biopsy in patients with FIGO 2018 stage T1A L1–T2A and negative preoperative lymph node imaging, and may help inform individualized surgical planning.

Supplementary data to this article can be found online at <https://doi.org/10.1016/j.ygyno.2025.09.018>.

## Funding

This work was supported by the Charles University Research Program *Cooperatio – Maternal and Childhood Care*, by the institutional grant of the General University Hospital in Prague (CZ-DRO-VFN64165), and by a grant from the Czech Health Research Council (NV19–03–00023). The funders had no role in the design of the study; in the collection, analysis, or interpretation of data; in the writing of the manuscript; or in the decision to publish the results.

## Disclosure statement

The authors report no conflict of interest.

## CRediT authorship contribution statement

**Roman Kocian:** Writing – review & editing, Writing – original draft, Visualization, Validation, Supervision, Resources, Project administration, Methodology, Investigation, Formal analysis, Data curation, Conceptualization. **Christhardt Kohler:** Writing – review & editing, Investigation. **Jaroslav Klat:** Writing – review & editing, Investigation. **Jiri Jarkovsky:** Writing – review & editing, Software, Formal analysis, Data curation. **Ignacio Zapardiel:** Writing – review & editing, Investigation. **Giampaolo Di Martino:** Writing – review & editing, Investigation. **Luc van Lonkhuijzen:** Writing – review & editing, Investigation. **Michal Zikan:** Writing – review & editing, Investigation. **Octavio Arencibia Sanchez:** Writing – review & editing, Investigation. **Blanca Gil-Ibanez:** Writing – review & editing, Investigation. **Francesco Raspagliesi:** Writing – review & editing, Investigation. **Jiri Presl:** Writing – review & editing, Investigation. **Lubos Minar:** Writing – review & editing, Investigation. **Radim Marek:** Writing – review & editing, Investigation. **Peter Kascak:** Writing – review & editing, Investigation. **Pavel Havelka:** Writing – review & editing, Investigation. **Martin Michal:** Writing – review & editing, Investigation. **Toon Van Gorp:** Writing – review & editing, Investigation. **Kristyna Nemejcova:** Writing – review & editing, Investigation. **Pavel Dundr:** Writing – review & editing, Investigation. **David Cibula:** Writing – review & editing, Writing – original draft, Supervision, Project administration, Methodology, Investigation, Funding acquisition, Data curation, Conceptualization.

## Acknowledgments

We would like to acknowledge the investigators from all 47 sites participating in the SENTIX trial. We also thank all medical specialists, data and case managers, secretaries, study coordinators, and other individuals involved in the study. Special thanks go to the physicians and project managers of the participating ENGOT groups, BGOG and CEEGOG, for their contributions to the successful conduct of the SENTIX trial. Above all, we sincerely thank all patients who participated in the study for their trust and contribution to research.

## References

- [1] D. Cibula, M.R. Raspollini, F. Planchamp, C. Centeno, C. Chargari, A. Felix, et al., ESGO/ESTRO/ESP guidelines for the management of patients with cervical cancer - update 2023, *Int. J. Gynecol. Cancer* 33 (5) (2023) 649–666.
- [2] D. Cibula, J. Dusek, J. Jarkovsky, P. Dundr, D. Querleu, A. van der Zee, et al., A prospective multicenter trial on sentinel lymph node biopsy in patients with early-stage cervical cancer (SENTIX), *Int. J. Gynecol. Cancer* 29 (1) (2019) 212–215.
- [3] F.R. Lecuru, M. McCormack, P. Hillemanns, A. Anota, M. Leitao, P. Mathevet, et al., SENTICOL III: an international validation study of sentinel node biopsy in early cervical cancer. A GINECO, ENGOT, GCIG and multicenter study, *Int. J. Gynecol. Cancer* 29 (4) (2019) 829–834.
- [4] H. Tu, H. Huang, B. Xian, J. Li, P. Wang, W. Zhao, et al., Sentinel lymph node biopsy versus pelvic lymphadenectomy in early-stage cervical cancer: a multi-center randomized trial (PHENIX/CSEM 010), *Int. J. Gynecol. Cancer* 30 (11) (2020) 1829–1833.
- [5] P.T. Ramirez, K.P. Robledo, M. Frumovitz, R. Pareja, R. Ribeiro, A. Lopez, et al., LACC trial: final analysis on overall survival comparing open versus minimally invasive radical hysterectomy for early-stage cervical cancer, *J. Clin. Oncol.* 42 (23) (2024) 2741–2746.

- [6] M. Plante, J.S. Kwon, S. Ferguson, V. Samouelian, G. Ferron, A. Maulard, et al., Simple versus radical hysterectomy in women with low-risk cervical Cancer, *N. Engl. J. Med.* 390 (9) (2024) 819–829.
- [7] D. Cibula, S. Marnitz, J. Jarkovsky, R. Kocian, P. Dundr, J. Klat, et al., Sentinel lymph node biopsy without systematic pelvic lymphadenectomy in females with early-stage cervical cancer: final outcome of the SENTIX prospective, single-arm, noninferiority, international trial, *Nat. Cancer* 6 (9) (2025) 1585–1594.
- [8] D. Cibula, R. Kocian, A. Plaikner, J. Jarkovsky, J. Klat, I. Zapardiel, et al., Sentinel lymph node mapping and intraoperative assessment in a prospective, international, multicentre, observational trial of patients with cervical cancer: the SENTIX trial, *Eur. J. Cancer* 137 (2020) 69–80.
- [9] R. Kocian, C. Kohler, S. Bajsova, J. Jarkovsky, I. Zapardiel, G. Di Martino, et al., Sentinel lymph node pathological ultrastaging: final outcome of the Sentix prospective international study in patients with early-stage cervical cancer, *Gynecol. Oncol.* 188 (2024) 83–89.
- [10] K. Nemejcova, R. Kocian, C. Kohler, J. Jarkovsky, J. Klat, A. Berjon, et al., Central Pathology Review in SENTIX, A Prospective Observational International Study on Sentinel Lymph Node Biopsy in Patients with Early-Stage Cervical Cancer (ENGOT-CX2), *Cancers (Basel)* 12 (5) (2020).
- [11] V. Balaya, A. Bresset, B. Guani, L. Magaud, R. Montero Macias, M. Delomenie, et al., Risk factors for failure of bilateral sentinel lymph node mapping in early-stage cervical cancer, *Gynecol. Oncol.* 156 (1) (2020) 93–99.
- [12] N. Bizzarri, G. Schivardi, G. Di Martino, A. Antonacci, D. Querleu, L. Pedone Anchora, et al., Factors associated with bilateral sentinel lymph node mapping failure using indocyanine green in patients with apparent early-stage cervical cancer: an Italian retrospective multi-center study, *Eur. J. Surg. Oncol.* 51 (7) (2025), 109981.
- [13] X. Zhang, B. Bao, S. Wang, M. Yi, L. Jiang, X. Fang, Sentinel lymph node biopsy in early stage cervical cancer: a meta-analysis, *Cancer Med.* 10 (8) (2021) 2590–2600.
- [14] L. Dostalek, M. Zikan, D. Fischerova, R. Kocian, A. Germanova, F. Fruhauf, et al., SLN biopsy in cervical cancer patients with tumors larger than 2cm and 4cm, *Gynecol. Oncol.* 148 (3) (2018) 456–460.
- [15] A. Buda, A. Papadia, I. Zapardiel, E. Vizza, F. Ghezzi, E. De Ponti, et al., From conventional radiotracer Tc-99(m) with blue dye to Indocyanine green fluorescence: a comparison of methods towards optimization of sentinel lymph node mapping in early stage cervical Cancer for a laparoscopic approach, *Ann. Surg. Oncol.* 23 (9) (2016) 2959–2965.
- [16] G. Di Martino, C. Crivellaro, E. De Ponti, B. Bussi, A. Papadia, I. Zapardiel, et al., Indocyanine green versus radiotracer with or without blue dye for sentinel lymph node mapping in stage >IB1 cervical Cancer (>2 cm), *J. Minim. Invasive Gynecol.* 24 (6) (2017) 954–959.
- [17] J. Persson, O. Luhrs, B. Geppert, L. Ekdahl, C. Lonnerfors, A prospective study evaluating an optimized sentinel node algorithm in early stage cervical cancer: the PROSACC-study, *Gynecol. Oncol.* 187 (2024) 178–183.
- [18] Y. Aoki, H. Kanao, A. Fusegi, M. Omi, S. Okamoto, T. Tanigawa, et al., Indocyanine green-guided sentinel lymph node mapping during laparoscopic surgery with vaginal cuff closure but no uterine manipulator for cervical cancer, *Int. J. Clin. Oncol.* 27 (9) (2022) 1499–1506.
- [19] S. Imboden, A. Papadia, M. Nauwerk, B. McKinnon, Z. Kollmann, S. Mohr, et al., A comparison of Radiocolloid and Indocyanine green fluorescence imaging, sentinel lymph node mapping in patients with cervical Cancer undergoing laparoscopic surgery, *Ann. Surg. Oncol.* 22 (13) (2015) 4198–4203.
- [20] A.L. Beavis, S. Salazar-Marioni, A.K. Sinno, R.L. Stone, A.N. Fader, A. Santillan-Gomez, et al., Sentinel lymph node detection rates using indocyanine green in women with early-stage cervical cancer, *Gynecol. Oncol.* 143 (2) (2016) 302–306.
- [21] J.H. Kim, D.Y. Kim, D.S. Suh, J.H. Kim, Y.M. Kim, Y.T. Kim, et al., The efficacy of sentinel lymph node mapping with indocyanine green in cervical cancer, *World J. Surg. Oncol.* 16 (1) (2018) 52.
- [22] T. Papathelemis, A. Scharl, M. Anapolski, A. Ignatov, O. Ortmann, et al., Value of indocyanine green pelvic lymph node mapping in the surgical approach of cervical cancer, *Arch. Gynecol. Obstet.* 301 (3) (2020) 787–792.
- [23] N. Bizzarri, P.A. Luigi, G. Ferrandina, G.F. Zannoni, M.V. Carbone, C. Fedele, et al., Sentinel lymph node mapping with indocyanine green in cervical cancer patients undergoing open radical hysterectomy: a single-institution series, *J. Cancer Res. Clin. Oncol.* 147 (3) (2021) 649–659.
- [24] M.A. Fernandez, H.D. Clark, M.D. Iniesta, M.F. Munsell, M. Frumovitz, P.T. Ramirez, Sentinel lymph node mapping with indocyanine green using SPY-PHI in open radical hysterectomy or trachelectomy, *Int. J. Gynecol. Cancer* 34 (1) (2024) 28–34.
- [25] J. Laufer, S. Scasso, A. Papadia, Impact of Indocyanine green dose on sentinel lymph node mapping in cervical Cancer: a systematic review, *Cancers (Basel)* 16 (17) (2024).
- [26] J.-h. Liu, Sentinel Lymph Node Biopsy Versus Pelvic Lymphadenectomy in Cervical Cancer: The Phenix-I Trial Annual Meeting on Women's Cancer, Seattle, WA, 2025.
- [27] P. Mathevet, F. Lecuru, C. Uzan, F. Boutitie, L. Magaud, F. Guyon, et al., Sentinel lymph node biopsy and morbidity outcomes in early cervical cancer: results of a multicentre randomised trial (SENTICOL-2), *Eur. J. Cancer* 148 (2021) 307–315.